



Newsletter of the Korean Stroke Society

⋮
⋮
⋮
⋮

28

: 02-2072-2875

<http://www.stroke.or.kr>

: 02-3673-1990

e-mail: kss1998@hitel.net

1

2004 10 25 , 499 , 217 ,
10 726 , Dr. Randall T.Higashida 11 .

6 2 1 , 6 , 4 가 1

가 가

가 .

9 6 ‘ ’ 11 6 ()

가 가 , 가 ,
1,000 ' 가 가 , ,



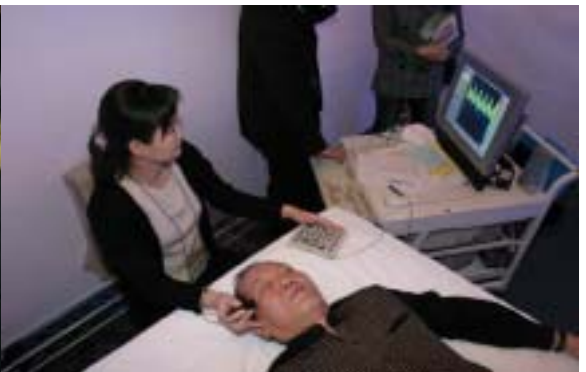Opening Ceremony



가 450 2




가



/ 가



(TCD)



/

6 1

“ , ”

- 2004

2004 가 2004 11 5 Hilton “Risk factors and
Neuroradiological intervention” 347 가

- 2

2004 11 27 -28 Pacifico Yokohama
Pacifico Yokohama convention center

1) Stroke situation in Korea and Japan (including risk factors), 2) Stroke prevention in Korea and Japan (including antiplatelets, anticoagulation et al), 3) Thrombolysis and antithrombotic therapy in Korea and Japan (including intravascular intervention), 4) Management of the stroke patients in chronic stage in Korea and Japan (including vascular dementia, surgical intervention etc) symposium
issue가

3

2006

가

2004 10

: 2004 10 11 () 6 30
:

- : Vascular dementia
- : Vertical diplopia with tiny midbrain lesion ()
- : 1. Vascular cognitive impairment (가)
- 2. Leukoaraiosis- Pathophysiology, neuroimaging, clinical significance ()

2004 12

: 2004 12 13 () 6 30
:

- : Intracranial atherosclerosis
- : 21-year old woman with fever, headache, and cardiac murmur ()
- : 1. Epidemiology, diagnosis and prognosis of intracranial atherosclerosis ()
- 2. Recent update on medical and interventional management ()

2005 1 ()

: 2005 1 17 () 6 30
: 가

- : Pathophysiology of stroke
- : 46-year old woman with stroke 8 month after burn ()
- 1: Pathophysiology of stroke: Update ()
- 2: Progressive stroke: Clinical and pathophysiological perspective ()

* 2005

3/14, 5/9, 7/11, 9/12, 11/14

.